

Outcomes of Abdominal Wall Reservoir Placement in Inflatable Penile Prosthesis Implantation: A Safe and Efficacious Alternative to the Space of Retzius

Doron S. Stember, MD,* Bruce B. Garber, MD,[†] and Paul E. Perito, MD[‡]

*Beth Israel Medical Center of Mount Sinai Health System, Department of Urology, New York, NY, USA; [†]Drexel University College of Medicine, Department of Urology, Philadelphia, PA, USA; [‡]Perito Urology, Coral Gables, FL, USA

DOI: 10.1111/jsm.12408

ABSTRACT

Introduction. Inflatable penile prosthesis (IPP) surgery is a successful therapeutic option for men with erectile dysfunction. Traditional placement of the reservoir in the retropubic space of Retzius is associated with the rare occurrence of significant complications including bladder, bowel, and vascular injury. An alternative site, posterior to the abdominal wall musculature, has been identified as a potentially safer location for reservoir placement.

Aims. The aim of this study was to describe our technique of abdominal reservoir placement during infrapubic IPP surgery and present our outcomes data.

Methods. We retrospectively reviewed our experience with abdominal reservoir placement during virgin IPP cases. Reservoirs placed anterior and posterior to transversalis fascia were analyzed separately.

Main Outcome Measure. The main outcome measures was assessment of reservoir-related complications including palpable reservoir, reservoir herniation, and injuries to bowel, bladder, or major blood vessels.

Results. There were no injuries to bowel or major blood vessels with abdominal reservoir placement posterior or anterior to the transversalis fascia in properly segregated patients.

Conclusion. Abdominal reservoir placement is a safe and simple surgical method that can be recommended for most men undergoing IPP placement. Men with a history of pelvic surgery can have the reservoir placed between the rectus abdominis musculature and transversalis fascia, while other men can have the reservoir placed between transversalis fascia and peritoneum in order to avoid a palpable reservoir. By applying this protocol, the catastrophic injuries that occur rarely with retropubic reservoir placement can be reliably avoided. **Stember DS, Garber BB, and Perito PE. Outcomes of abdominal wall reservoir placement in inflatable penile prosthesis implantation: A safe and efficacious alternative to the space of Retzius. J Sex Med **;**:**_**.**

Key Words. Penile Prosthesis Reservoir; Penile Prosthesis Complications; Reservoir Complications; Abdominal Reservoir; Ectopic Reservoir

Introduction

Inflatable penile prostheses (IPPs) have been a successful therapeutic option for men with erectile dysfunction (ED) for the past 40 years. Traditionally, the reservoir has been placed in the pre-vesical or retroperitoneal space. Although complications are rare, serious viscus or vascular injury can occur [1]. To minimize the risk of these adverse outcomes, alternative sites for abdominal reservoir placement have been described [2–4]. A recent survey of high-volume prosthetic surgeons

indicated that 90% believe placing the reservoir in an “ectopic” location (i.e., different from the space of Retzius) can be advantageous for patient safety [5].

This is a retrospective study of a single surgeon who employed reservoir placement posterior to the transversalis fascia (PTF) in most first-time implant patients. Patients with anatomic issues underwent reservoir placement anterior to transversalis fascia (ATF). We compared outcomes of the two groups and question whether the avoidance of serious complications with these

techniques might prompt consideration of a change from the traditional location of the IPP reservoir.

Methods

A consecutive series of 2,687 men who underwent first-time IPP via an infrapubic incision between January 2002 and December 2012 comprised the study population. Eighty-three percent (2,239) had reservoirs placed in the PTF space. The remaining 17% (447) were deemed to have anatomic issues making reservoir placement potentially problematic. These men underwent reservoir placement in the ATF space and were counseled about the possibility of a visible or palpable reservoir bulge. This latter group included patients with a past surgical history of radical retropubic prostatectomy (RRP) (82%), colon surgery (11%), cystectomy, herniorrhaphy, or aortofemoral bypass (7%). The Coloplast Titan (Coloplast, Minneapolis, MN, USA) was used in all patients.

In 2010, Coloplast introduced the Cloverleaf® reservoir. This reservoir has a bellows-like configuration that allows it to be quite flat when underfilled but cylindrical when fully expanded. We used this low profile reservoir in all cases since it became available. We usually used 125 cc reservoirs and filled them with 70–85 cc of saline. Less often, we used 60 cc reservoirs and filled them with 40–50 cc.

Patients with a history of prior IPP surgery were excluded from this analysis. We gathered data on preoperative history of pelvic surgery and intraoperative complications for both the ATF and PTF groups. Follow-up visits up to 24 months were analyzed for adverse events and patient dissatisfaction with reservoir position.

Surgical Technique

The initial steps of reservoir placement are identical for both ATF and PTF. The bladder is emptied preoperatively by voiding or catheterization. A transverse infrapubic incision is made, and the cylinders are placed. The pubic tubercle is used as a landmark for guiding the finger into the external inguinal ring. An 80 mm closed nasal speculum is then slipped along the ventral aspect of the finger and into the ring.

PTF Reservoir Insertion

For men with no prior history of significant pelvic surgery, the speculum handle tip is used to perfo-

rate transversalis fascia in a downward fashion. The handle is then rotated so that the orientation of the speculum tip is changed from posterior to cephalad. The instrument is then advanced to the handle in a cephalad fashion. The nasal speculum paddles are spread to dilate the potential space. Air is evacuated from the reservoir, and it is inserted through the spread paddles. Care is taken to keep the lockout mechanism anterior to prevent invalidation by adjacent structures.

ATF Reservoir Insertion

In patients with a history of significant pelvic surgery, after the tip of the nasal speculum is passed through the external ring, it is forcibly advanced cephalad. The back wall of the inguinal canal is thus perforated without perforation of transversalis fascia. The speculum is advanced the length of the paddles. This places the speculum ATF but posterior to the overlying rectus abdominis muscles. Because the speculum is 80 mm long, the tip is approximately 3 inches above the inguinal ring. The paddles are spread, elevating the abdominal wall muscles and creating a space for the reservoir that is passed through the paddles.

With both ATF and PTF techniques, the reservoir is fashioned into a “cup” shape by spreading the Cloverleaf® reservoir sides laterally as air is evacuated. This maneuver facilitates deployment of the reservoir into the newly created submuscular tunnel. A small pediatric Yankauer tip is placed into the depression of the cup (Figure 1) and used to pass the reservoir as far cephalad as possible (Figure 2) between the maximally spread speculum.

The anatomical relationship between the reservoir and abdominal wall layers is depicted for ATF and PTF placement, respectively, in Figures 3 and 4. In summary, peritoneum, transversalis fascia, and vital structures are posterior to the reservoir with ATF while only peritoneum is posterior with PTF.

Outcomes

We desired to compare ATF and PTF reservoir placement patient outcomes to see if these new techniques could be recommended. A retrospective chart review was conducted. Patient demographics, perioperative data, and postoperative visit data were collected and analyzed. Follow-up visit data were collected at 1, 3, 6, 12, and 24 months for all men. Data on patients with adverse

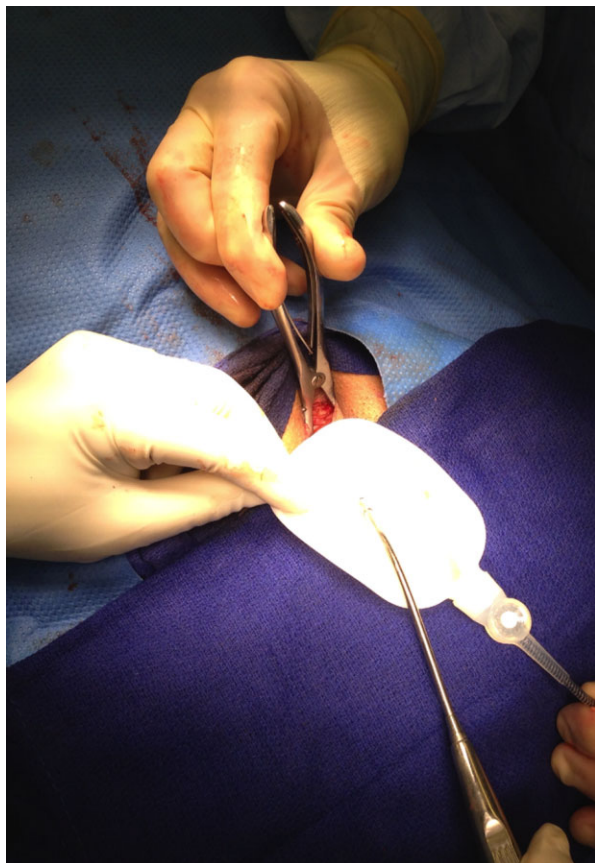


Figure 1 The reservoir is fashioned into a cupped shape to accommodate the pediatric Yankauer suction tip

outcomes were additionally collected at the time of complication presentation.

Results

A total of 2,687 men met criteria for study inclusion. Two thousand two hundred thirty-nine men had reservoirs placed PTF. During implantation, two patients had bladder perforation during the initial pass of the nasal speculum. These two patients had failed to empty completely preoperatively. After detection of the laceration, the reservoir was placed on the contralateral side and Foley catheter drainage was utilized for 7 days. No attempt was made to repair the laceration, and both patients had otherwise uncomplicated courses. Two patients (0.09%) had sustained coughing immediately postoperatively and developed reservoir herniation. These patients required revision surgery through the same incision to replace the reservoir in its proper location. Twenty-one patients (0.94%) developed device infection requiring removal.

The ATF group of 447 patients included 2 patients bothered enough by palpable reservoir that they elected revision surgery. Fifteen other patients (3.4%) could feel the reservoir in the early postoperative period but became satisfied after 6 months and did not seek additional correction. Six patients (1.34%) developed postoperative reservoir herniation into the inguinal canal. These patients underwent additional surgery to replace the reservoir higher in the abdominal wall. Six patients (1.34%) developed device infection requiring removal.

Infected implants in both groups were removed by opening the original incision without additional incisions for reservoir removal. When comparing differences in rates of complications between the ATF and PTF groups, the incidence of reservoir

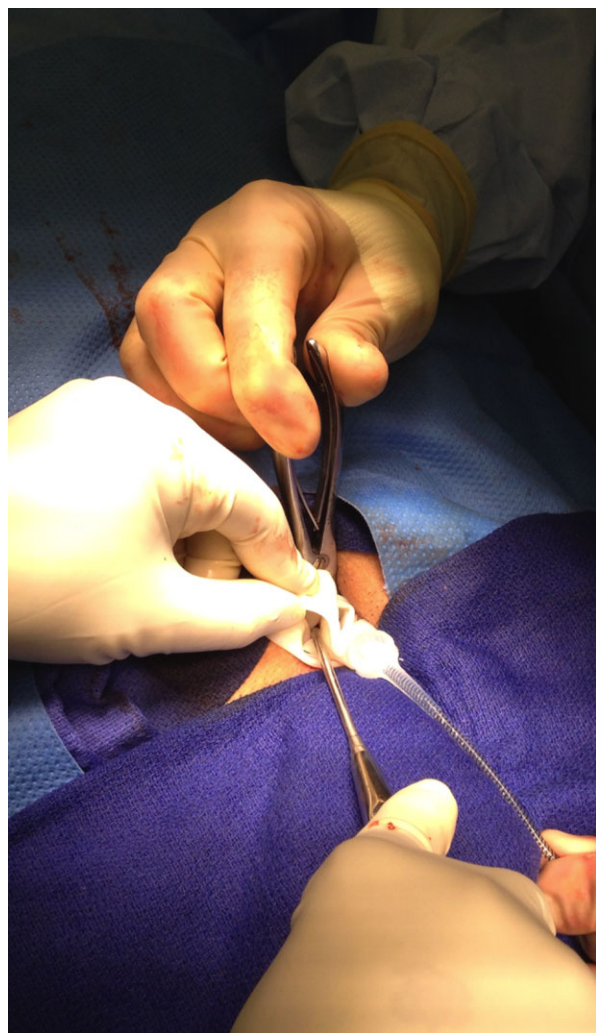


Figure 2 The Yankauer suction tip is utilized to deliver the reservoir into the abdominal wall space via the infrapubic incision

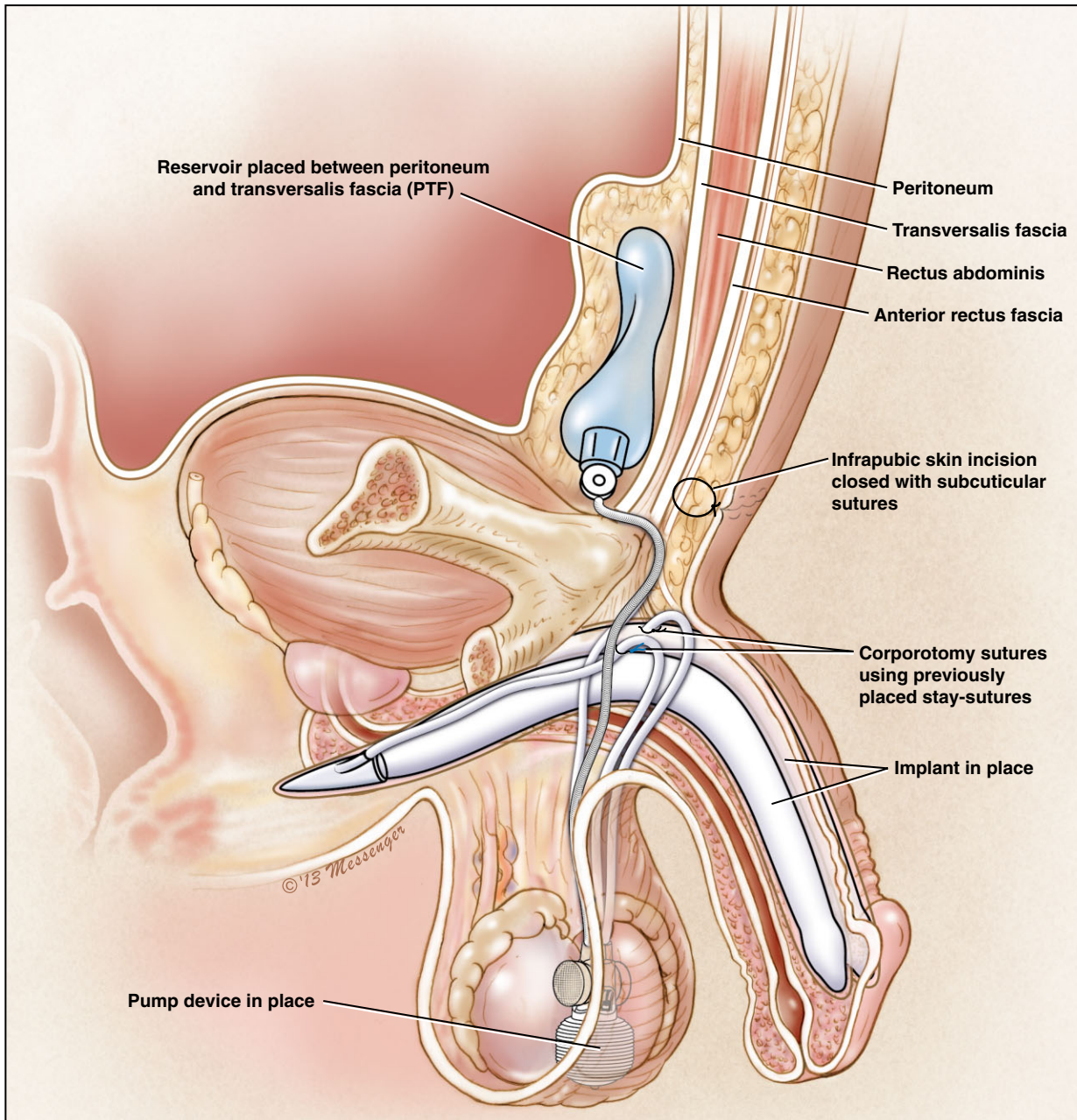


Figure 3 PTF (posterior to transversalis fascia) reservoir placement

herniation was the only parameter that reached statistical significance (1.34% for ATF vs. 0.09% for PTF, $P < 0.001$).

The complications in our series are summarized in Table 1.

Discussion

The goal of IPP placement in men with ED is to improve quality of life by resumption of sexual

activity. Although serious complications such as vascular, bladder, and bowel injuries are rare, they have been associated with retropubic reservoir placement and are disastrous when they occur. If we can identify those patients most at risk of viscus or vessel injury and use an alternative location, would it be worth the risk of an occasional palpable reservoir or rare reservoir hernia? We hypothesized that placement of the reservoir in an abdominal wall location would provide a location

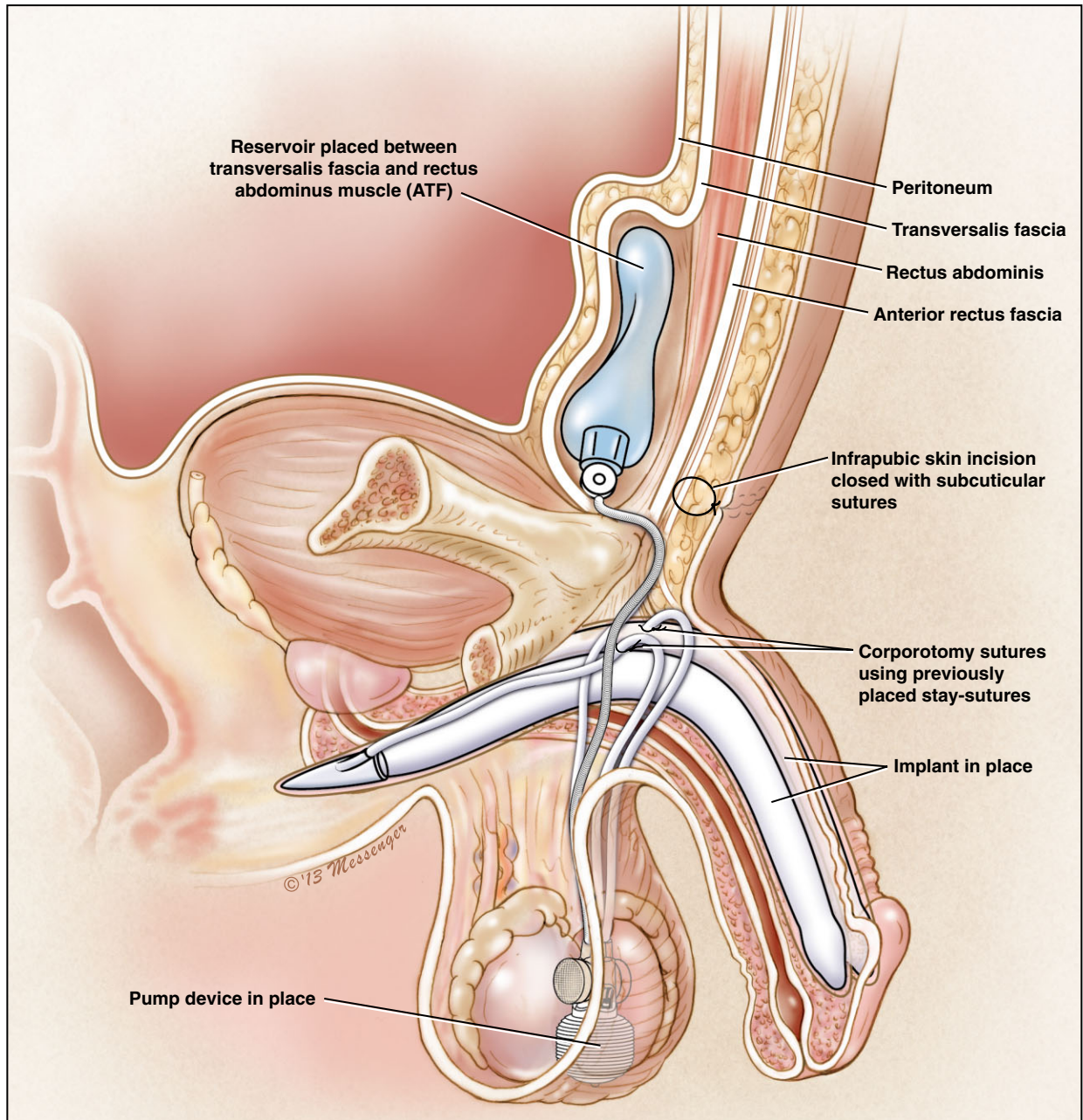


Figure 4 ATF (anterior to transversalis fascia) reservoir placement

Table 1 Complications of abdominal wall reservoir placement

Reservoir location	n	Bladder injury	Herniation	Revision for palpable reservoir	Autoinflation	Infection (%)
ATF	447	0	6 (1.34%)	2 (0.45%)	2 (0.45%)	6 (1.34%)
PTF	2,239	2 (0.09%)	2 (0.09%)	0	0	21 (0.94%)
<i>P</i> value*		1.000	<0.001	0.028	0.028	0.435

*Fisher's Exact Test (two-sided)

ATF = anterior to transversalis fascia; PTF = posterior to the transversalis fascia

anatomically removed from any viscus or significant vessel. This should eliminate the possibility of a catastrophic complication occurring in a patient seeking elective correction of what could be considered a quality of life illness.

Vascular Injuries

Henry et al. reported on a cadaver study [6] showing the external inguinal ring was only 2.5–4 cm from the external iliac vein, 5.3–8 cm from the decompressed bladder, and 2–4 cm from the filled bladder. The proximity of the gateway to reservoir placement—the inguinal ring—to both the external iliac vein and bladder explains both the occasional laceration of these structures during routine implantation (as in our series) and the increased risk of complication in patients whose anatomy has been altered.

With traditional reservoir placement in the space of Retzius, iliac vein compromised by laceration or reservoir pressure causing thrombosis has been reported in the literature on multiple occasions [7–10]. Previous pelvic surgery, as noted in these reports, obviously alters the surgical planes and makes the injury more likely.

When removal of a retropubic reservoir is required for mechanical failure or infection, there is also a risk of vascular injury. Levine and Hoeh reported this complication accompanied by life-threatening bleeding [11]. On occasion, a surgeon different from the original implanter performs reservoir removal. Experience has shown us that these situations are more likely to be accompanied by severe bleeding during reservoir removal. This has led us to the policy of leaving the reservoir behind in uninfected IPP revisions. Hinds et al. have studied the dilemma of “drain and retain” in depth in a recent publication [12].

Utilization of the PTF or ATF spaces should preclude patients from catastrophic vascular injury during either placement or removal of reservoirs. No vessel injuries occurred in the nearly 2,700 cases reported in this article. Although this is a single surgeon series, it would be similarly optimal for less experienced implanting surgeons to utilize a reservoir location where severe bleeding could not possibly occur.

Bladder Injuries

The proximity of the inguinal ring to the bladder requires that it be emptied of urine prior to reservoir placement. Henry et al.’s cadaver study showed a full bladder is as close as 2 cm to the

inguinal ring [6]. All experienced implanters have performed cystoscopy on IPP patients and seen the imprint of the reservoir of the superior bladder wall as the bladder fills with irrigation fluid. The literature is replete with case reports of bladder laceration or erosion related to reservoir placement [13–18]. Erosion seems more likely in men with a history of RRP [13,14]. Delayed erosion of reservoirs into the bladder has occurred as late as 4 years following IPP placement [15]. Inadvertent placement of reservoir into the bladder at the time of surgery is another complication that has been reported with retropublic placement [19]. Finally, there have been two reports of ureteral obstruction following retropublic reservoir placement [20,21].

Could a reservoir location that is not contiguous to the bladder be utilized without impacting patient satisfaction or creating new complications? In our opinion, ATF and PTF placement meet these criteria. There were no cases of erosion into the bladder in our series. The only danger point relative to the bladder with our approach is acute laceration at the time of implantation. Our preoperative protocol therefore requires the patient to empty his bladder before surgery. Our two instances of bladder laceration during PTF placement were associated with a failure of the protocol, and we are considering catheterizing every patient before surgery to avoid future complications.

Bowel Injuries

There are multiple reported cases of bowel laceration, obstruction, or reservoir erosion as a complication following retropubic reservoir placement [22–27]. With the advent of robot-assisted laparoscopic radical prostatectomy, in which the peritoneal veil may not have been reconstituted, the likelihood of inadvertent intraperitoneal IPP reservoir placement is increased. Intraperitoneal placement may result in bowel erosion or laceration [22]. Similarly, during colectomy and cystoprostatectomy surgery, the retropubic/retroperitoneal space is largely obliterated and bowel fills the void, creating a risk factor for bowel injury related to IPP reservoir [23,24]. All these clinical situations have in common reservoir placement into a location postsurgically filled with bowel. ATF placement of the reservoir avoids any possibility of bowel damage without the necessity of a time-consuming second incision in this situation.

Palpation of Abdominal Wall Reservoir and Herniation

In the context of the above list of possible catastrophic complications associated with traditional reservoir placement, the possible downsides of a reservoir placement method that allows the surgeon to avoid these complications must be considered. As shown by this study, a patient's ability to appreciate a palpable or visible bulge with ATF placement is a potential downside. Reservoir palpability is more likely to occur in slender patients. This series shows that 3.4% ($n = 15$) of patients feel the reservoir in the immediate postoperative period, but only two desired corrective surgery. We attribute this tolerance to the problem to thorough preoperative counseling about the possibility that the patient may feel the reservoir. Preoperative counseling that includes accurate description of the procedure and the setting of realistic patient expectations results in higher patient satisfaction after IPP placement [28]. We also believe that subsequent capsule formation around the reservoir makes it less bothersome with time. Furthermore, it should be noted that many other implanted medical devices are associated with the patient's ability to palpate a component. We consider a possible small abdominal bulge from ATF reservoir placement an acceptable compromise to avoid the possibility of viscus or vessel complication.

In an attempt to mitigate reservoir bulge, we have changed our surgical technique. Initially, we directed the nasal speculum toward the ipsilateral shoulder. We now direct the speculum tip, and subsequently reservoir placement, in a strict cephalad-caudad orientation. This placement close to the midline results in concealment of the reservoir beneath the prominent portion of the rectus muscle. We have no data to prove it yet, but our feeling is that this enhancement decreases the incidence of patient complaints.

Presentation of the reservoir in an inguinal location as a palpable groin hernia is a complication we should strive to prevent. It occurred following surgery placement in 1.3% of the ATF group and was statistically significant compared with the PTF group. We have modified our method to include the placement of vicryl stitch to tighten the fascia near the point where the tubing exits the reservoir site in cases where we suspect that the tunnel to the reservoir is capacious enough to permit herniation.

Morey et al. have recently described their approach to abdominal wall reservoir placement using lung grasping clamps that are considerably longer than the 80 mm of the nasal speculum and pediatric Yankauer [29]. Perhaps, utilization of the lung grasping clamp could decrease the incidence of ATF herniation by requiring that the reservoir travel a longer distance to become a hernia.

One factor precluding general acceptance of ATF and PTF reservoir sites as a valid alternative to traditional space of Retzius placement is that ATF/PTF reservoir placement has not been approved by the Federal Drug Administration (FDA). At present, it represents an "off-label" use of the reservoir. While both implant manufacturers market new "flat" reservoirs (American Medical Systems Conceal® and Coloplast Cloverleaf®), they are prohibited from making the representation that the low reservoir profile lends itself to a location alternative to the traditional placement site. Hopefully, investigations such as the present one will prompt further study and eventual certification by the FDA.

Conclusions

Abdominal wall/ATF placement of an IPP reservoir is a relatively simple technique that can avoid the possibility of catastrophic complications associated with traditional retroperitoneal reservoir placement. We recommend ATF placement for patients with the risk factor that their pelvic anatomy has been altered by previous surgery. PTF placement offers a similar advantage for patients with virgin pelvis.

The major drawbacks to ATF use in all patients are palpable or visible reservoir and inguinal reservoir hernia development. The new flat reservoirs have enhanced our enthusiasm for the ATF and PTF placement methods described in this article. Considerable abdominal wall reservoir placement experience by our group and others is leading to refinements in surgical technique. We hope to eventually reduce reservoir bulge and herniation to a degree acceptable to allow us to recommend the procedure to all recipients of an IPP.

Corresponding Author: Doron S. Stember, MD, Beth Israel Medical Center of Mount Sinai Health System, Department of Urology, New York, NY 10003, USA. Tel: 2128448900; Fax: 2128448901; E-mail: dstember@chpnet.org

Conflict of Interest: Dr. Garber is a consultant for Coloplast. Dr. Perito is a consultant for Coloplast and AMS. Figures 3 and 4 were supplied by Coloplast.

Statement of Authorship**Category 1****(a) Conception and Design**

Paul E. Perito; Bruce B. Garber; Doron S. Stember

(b) Acquisition of Data

Paul E. Perito

(c) Analysis and Interpretation of Data

Paul E. Perito; Bruce B. Garber; Doron S. Stember

Category 2**(a) Drafting the Article**

Paul E. Perito; Bruce B. Garber; Doron S. Stember

(b) Revising It for Intellectual Content

Paul E. Perito; Bruce B. Garber; Doron S. Stember

Category 3**(a) Final Approval of the Completed Article**

Paul E. Perito; Bruce B. Garber; Doron S. Stember

References

- 1 Garber BB, Morris A. Intravesical penile implant reservoir: Case report, literature review, and strategies for prevention. *Int J Impot Res* 2012;25:41–4.
- 2 Perito PE, Wilson SK. Traditional (retroperitoneal) and abdominal wall (ectopic) reservoir placement. *J Sex Med* 2011;8:656–9.
- 3 Perito PE. Ectopic reservoir placement—No longer in the space of Retzius. *J Sex Med* 2011;8:2395–8.
- 4 Wilson SK, Henry GD, Delk JR Jr, Cleves MA. The mentor Alpha 1 penile prosthesis with reservoir lock-out valve: Effective prevention of auto-inflation with improved capability for ectopic reservoir placement. *J Urol* 2002;168:1475–8.
- 5 Karpman E, Sadeghi-Nejad H, Henry GD, Khera M, Morey AF. Current opinions on alternative reservoir placement for inflatable penile prosthesis among members of the Sexual Medicine Society of North America. *J Sex Med* 2013;10:2115–20.
- 6 Henry G, Jones L, Carrion R, Bella A, Karpman E, Christine B, Kramer A. Pertinent anatomical measurements of the retropubic space: A guide for inflatable penile prosthesis reservoirs shows that the external iliac vein is much closer than thought. *J Sex Med* 2012;9(suppl 4):192, A27.
- 7 da Justa DG, Bianco FJ Jr, Ogle A, Dhabuwal CB. Deep venous thrombosis due to compression of external iliac vein by the penile prosthesis reservoir. *Urology* 2003;61:462v–vi.
- 8 Brison D, Ilbeigi P, Sadeghi-Nejad H. Reservoir positioning and successful thrombectomy for deep venous thrombosis secondary to compression of pelvic veins by an inflatable penile prosthesis reservoir. *J Sex Med* 2007;4:1185–7.
- 9 Deho F, Henry GD, Marone EM, Sacca A, Chiesa R, Rigatti P, Montorsi F. Severe vascular complication after implantation of a three-piece inflatable penile prosthesis. *J Sex Med* 2008;5:2956–9.
- 10 Flanagan MJ, Krisch EB, Gerber WL. Complication of a penile prosthesis reservoir: Venous compression masquerading as a deep venous thrombosis. *J Urol* 1991;146:847–8.
- 11 Levine LA, Hoeh MP. Review of penile prosthetic reservoir: Complications and presentation of a modified reservoir placement technique. *J Sex Med* 2012;9:2759–69.
- 12 Hinds PR, Wilson SK, Sedeghi-Nejad H. Dilemmas of inflatable penile prosthesis revision surgery: What practices achieve the best outcomes and lowest infection rates. *J Sex Med* 2012;9:2484–92.
- 13 Furlow WL, Goldwasser B. Salvage of the eroded inflatable penile prosthesis: A new concept. *J Urol* 1987;138:312–4.
- 14 Eldefrawy A, Kava BR. An unusual complication during inflatable penile prosthesis implantation. *Urology* 2010;76:847.
- 15 Dupont MC, Hochman HI. Erosion of an inflatable penile prosthesis reservoir into the bladder, presenting as bladder calculi. *J Urol* 1988;139:367–8.
- 16 Brusky J, Dikranin A, Aboseif S. Retrieval of inflatable penile prosthesis reservoir from the bladder. *Int J Impot Res* 2005;17:302–3.
- 17 Fitch WP 3rd, Roddy T. Erosion of inflatable penile prosthesis reservoir into bladder. *J Urol* 1986;136:1080.
- 18 Kramer AC, Chason J, Kusakabe A. Report of two cases of bladder perforation caused by reservoir of inflatable penile prosthesis. *J Sex Med* 2009;6:2064–7.
- 19 Volk S. The Legacy. *Phillymag.com*. October 2008; 78–81, 122–6.
- 20 Jiann BP, Ou CW, Lin JT, Huang JK. Compression of ureter caused by a retained reservoir of penile prosthesis. *Int J Impot Res* 2006;18:316–7.
- 21 Hudak SJ, Mora RV. Unilateral ureteral obstruction due to a migrated inflatable penile prosthesis reservoir. *J Urol* 2008;180:336.
- 22 Sadeghi-Nejad H, Munarriz R, Shah N. Intra-abdominal reservoir placement during penile prosthesis surgery in post-robotically assisted laparoscopic radical prostatectomy patients: A case report and practical considerations. *J Sex Med* 2011;8:1547–50.
- 23 Nelson RP Jr. Small bowel obstruction secondary to migration of an inflatable penile prosthesis reservoir: Recognition and prevention. *J Urol* 1988;139:1053–4.
- 24 Godiwalla SY, Beres J, Jacobs SC. Erosion of an inflatable penile prosthesis reservoir into an ileal conduit. *J Urol* 1987;137:297–8.
- 25 Leach GE, Shapiro CE, Hadley R, Raz S. Erosion of inflatable penile prosthesis reservoir into bladder and bowel. *J Urol* 1984;131:1177–8.
- 26 Luks FI, Huntley HN, Tula JC, Pizzi WF. Small-bowel obstruction by an inflatable penile prosthesis reservoir. *Surgery* 1989;106:101–4.
- 27 Singh I, Godec CJ. Asynchronous erosion of inflatable penile prosthesis into small and large bowel. *J Urol* 1992;147:709–10.
- 28 Kramer AC, Schweber A. Patient expectations prior to coloplast titan penile prosthesis implant predicts postoperative satisfaction. *J Sex Med* 2010;7:2261–6.
- 29 Morey AF, Cefalu CA, Hudak SJ. High submuscular placement of urologic prosthetic balloons and reservoirs via transscrotal approach. *J Sex Med* 2013;10:603–10.